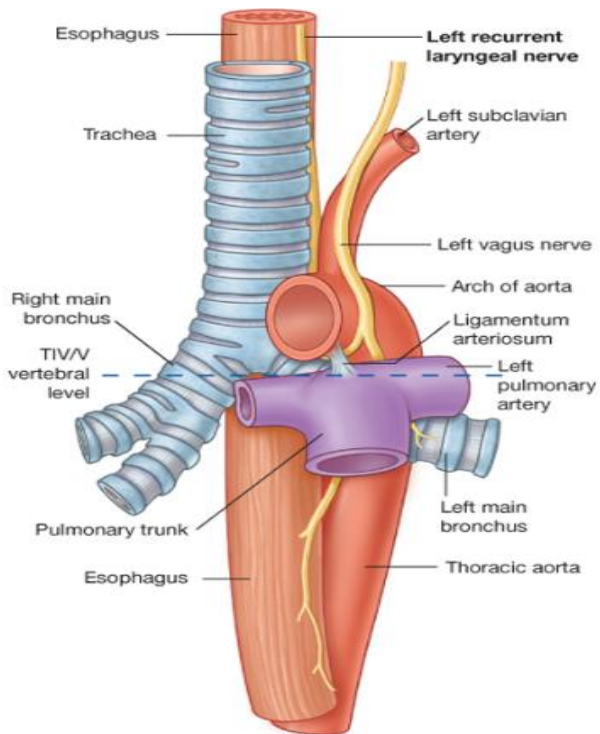
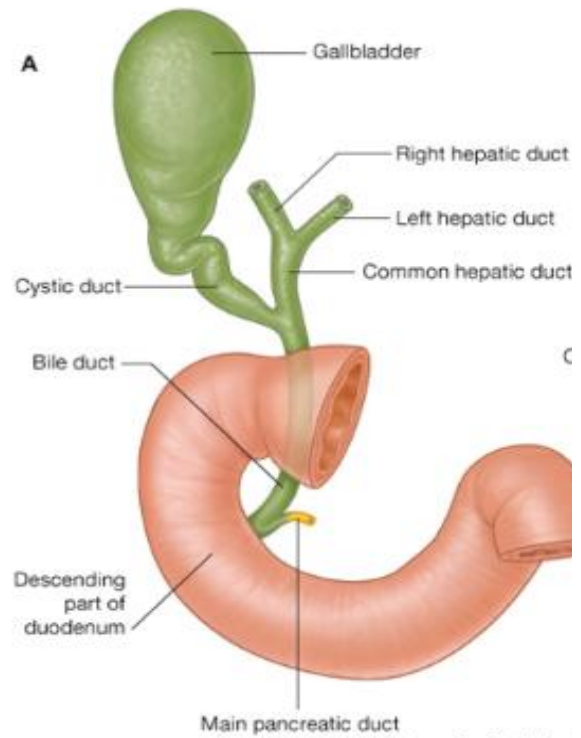


Afbeelding 1

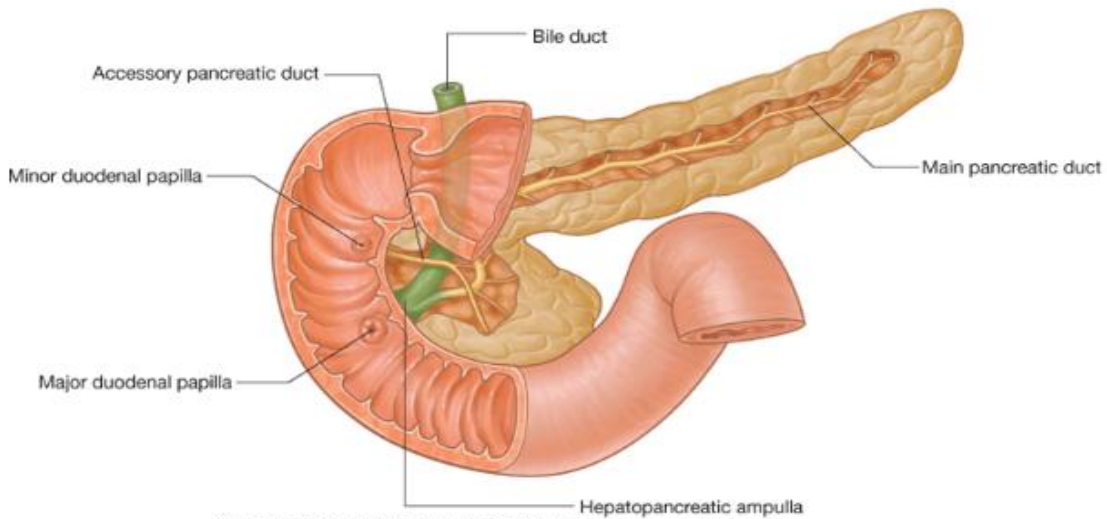


Drake: Gray's Anatomy for Students, 2nd Edition.  
 Copyright © 2009 by Churchill Livingstone, an imprint of Elsevier, Inc. All rights reserved.  
 Left recurrent laryngeal nerve passing through the superior mediastinum.

Afbeelding 2

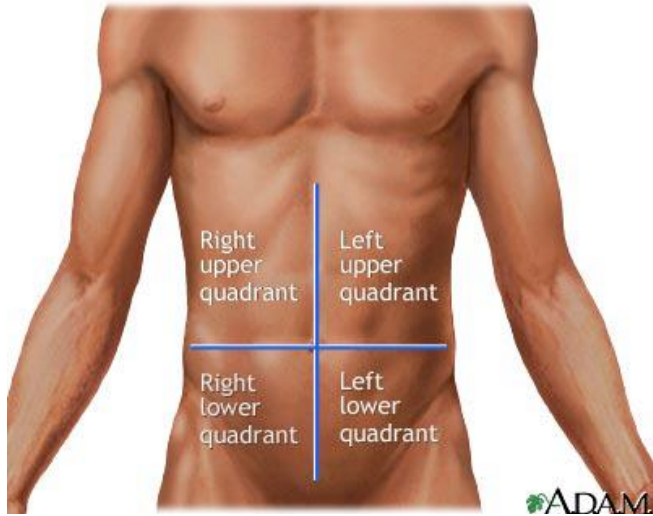


Afbeelding 3



Drake: Gray's Anatomy for Students, 2nd Edition.  
 Copyright © 2009 by Churchill Livingstone, an imprint of Elsevier, Inc. All rights reserved.

Afbeelding 4



[www.medicalimages.allrefer.com](http://www.medicalimages.allrefer.com), last updated 23 november 2010